

Management of Immediate Complete Denture, Overdenture, And Telescopic Denture of Patient with Parkinson's Disease (Case Report)

Haslinda Zainuddin Tamin¹, Veronica Angelia²

Department Of Prosthodontics Faculty Of Dentistry, University Of Sumatera Utara, Jalan Alumni No.2 Kampus USU Medan

Abstract: Parkinson's disease (PD) is a progressive neurologic disorder causing tremor, muscle rigidity, bradykinesia and postural instability. Generally, PD patient has oral health problems, such as xerostomia or sialorrhea, burning-mouth syndrome, more missing teeth, caries and poor oral hygiene. Involuntary of orofacial-pharyngeal muscles, tremor of mouth and chin may lead to difficulty of PD patient treatment. This case report describes preparation before treatment, modification of technique and material for PD patient with fabrication maxillary immediate complete denture, mandibular overdenture and telescopic denture. A female patient, 60 years old, was referred to Dental Hospital University of Sumatera Utara with complaint difficulty in mastication and poor esthetic. Patient was suffering PD since 8 years ago. Extra oral examination revealed a restricted lip movement and fixed gaze. Intra oral examination revealed only tooth 11 in maxilla and teeth 44, 42, 41, 31, 32 in mandible. Prosthodontist should consult a treatment plan with neurologist who treat the patient. Patient should take a medicine according to neurologist instructions, 60 minutes before starting the treatment, treatment should be done in the morning about 45 minutes and accompanied with closed family. Treatment for this case was preprosthetic procedure for remaining teeth, fabricating maxillary immediate complete denture with glass fiber reinforced, mandibular overdenture of tooth 44 and telescopic denture of abutment teeth 42,41,31,and 32. The tooth 11 was extracted utilizing 1 cartridge of 2% lidocaine HCl with epinephrine 1:100000, followed with insertion maxillary immediate complete denture and mandibular denture. Knowledge and empathy were essential in management of maxillary immediate complete denture, mandibular overdenture and telescopic denture thus improved difficulty in chewing, esthetic, and quality of life of PD patient.

Keywords: Parkinson's disease (PD), immediate complete denture, overdenture, telescopic denture.

I. Introduction

Parkinson's disease (PD) is a progressive neurological condition, resulting from the degeneration of dopamine-producing neurones in the substantia nigra, which is located within the basal ganglia, deep in the lower region of the brain, on either side of the brain stem. Clinical signs of Parkinson's disease are evident when about 80% of the dopamine-producing neurons are lost. Dopamine is a major neurochemical messenger that promotes the functions of the basal ganglia, which is also where the dopamine is produce and enables muscles to make smooth controlled movements. Statically, men are slightly more likely to develop the condition than women. The risk of developing Parkinson's disease increases with age, and symptoms often appear after the age of 50. Some people may not be diagnosed until they are in their seventies or eighties.¹ Increased mortality depends on disease duration and often results from infection.^{1,2}

Most Parkinson's disease is idiopathic and people who have an affected first-degree relative are at three times greater risk of developing it themselves. Parkinson's disease may be caused by cerebrovaskular disease, head injury (particularly in boxers), drugs [particularly phenothiazines and butyrophenones (dopamine receptor blockers), valproate, metoclopramide and prochlorperazine], and (rarely) encephalitis lethargica (von Economo disease). Parkinson's disease is more common in people engaged in farming (the use of herbicides and pesticides), living in rural areas or who drink well water. Lower oestrogen levels may also raise the risk of Parkinson's disease for menopausal women.²

The main motor symptoms of Parkinson's disease are bradykinesia (slowness of movement), rigidity (raised tone, which may be asymmetrical, or limited to certain muscle groups), tremor (involuntary shaking, trembling or quivering movements of the muscles) and postural instability (balance problems). People with Parkinson's disease develop a lack of facial expression with a characteristic 'mask-like' face, reduced blinking rate, drolling, a quite monotone voice, short stuffing steps, gait instability, anxiety disorder, apathy, depression, psychosis and visual hallucinations, dementia, sleep disturbances, autonomic disturbance (urinary dysfunction, constipation, sexual dysfunction, orthostatic/postural hypotension, weight loss, dysphagia, hyperhidrosis, sialorrhoea) and sensory disturbance.^{1,2}

Parkinson's disease is divided into stages according to Hoehn and Yahr. These stage are: mild/early disease (Stage 1: only one side of the body is affected, usually with minimal or no functional impairment; and Stage 2: both sides of the body are affected, but posture and balance remain normal); moderate disease (Stage 3: both sides of the body are affected and there is mild imbalance when standing or walking); and advanced disease (Stage 4: both sides of the body are affected and there is disabling instability while standing or walking; i.e. the person requires substantial help and cannot live alone; and Stage 5: severe, fully developed disease is present, i.e. the person is often cachectic and restricted to bed or a wheelchair unless aided).³

Patients with Parkinson's disease seems to have more missing teeth, caries, dental plaque and food debris, poorer oral clearance, xerostomia or sialorrhea, burning-mouth syndrome and periodontal health, which have been ascribed to a lack of orofacial muscular control, hyposalivation, and compromised manual dexterity. Orofacial disfunction, masticaton and jaw opening poorer. The jaw mobility and the speed of the jaw movements are reduced. The rigidity, the reduced mobility and the tremor complicate the formation and the placement of the food bolus and the chewing process, food retention and dysphagia. In Parkinson's disease, 30-80% of patients have drooling of saliva in the mouth as the result of dysphagia, decreased swallowing frequency, diminished closure of the lips and antecollis. All of these may lead to difficulty of Parkinson's disease patient treatment.⁴

This case report describes preparation before treatment, modification of technique and material for Parkinson's disease patient with fabrication maxillary immediate complete denture, mandibular overdenture and telescopic denture.

II. Case Report

A female patient, 60 years old, was referred to Dental Hospital University of Sumatera Utara with complaint difficulty in mastication and poor esthetic. Patient never used denture before. Medical history revealed that the patient was suffering Parkinson's disease since 8 years ago and was under medication by neurologist. She complained tremor, demensia and sleep disturbance. Past dental history included root extraction 9 months ago and scaling 3 months ago. She was able to communicate with the speech of the patient was soft, hurried and monotonous. She did not show signs of depression and was highly motivated to replace her missing teeth.

Extraoral examination revealed square tapering facial form and convex profile (Figure 1). A reduced blink rate and reduction in tear film which led to irritated eye surface and also had a fixed gaze (Figure 2). Restricted lip movement was observed when trying to explain something in a conversation. Examination of neuromuscular coordination elicited an interrupted jerky movement of the mandible.

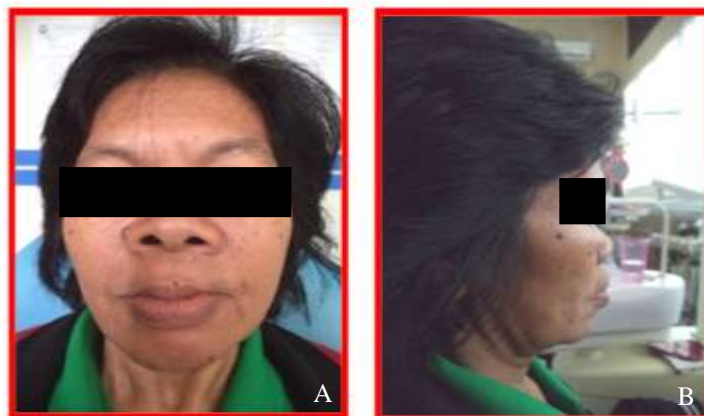

Figure 1. Before prosthodontic treatment: (A) square tapering facial form; (B) convex profile



Figure 2. Fixed gaze of Parkinson's disease

Intra oral examination revealed only tooth 11 in maxilla and teeth 32, 31, 41, 42, 44 in mandible. Teeth 11, 32, 31, 41, 42, 44 are caries and mobility stage 1. Teeth 11 1,5 mm elongation, labioversion and mesial migration, $\pm 0,5$ mm attrition (Figure 3). Panoramic radiograph examination revealed no presence of retained root tips, impacted teeth, foreign bodies (Figure 4). Periapical radiograph examination revealed tooth 11 with caries profunda at servical, tooth 31 pulp necrosis, tooth 32 chronic apical periodontitis ec pulp necrosis, tooth 41 chronic apical periodontitis ec pulp necrosis, tooth 42 pulp necrosis and tooth 44 pulp necrosis (Figure 5). Tongue movement is uncontrolled.

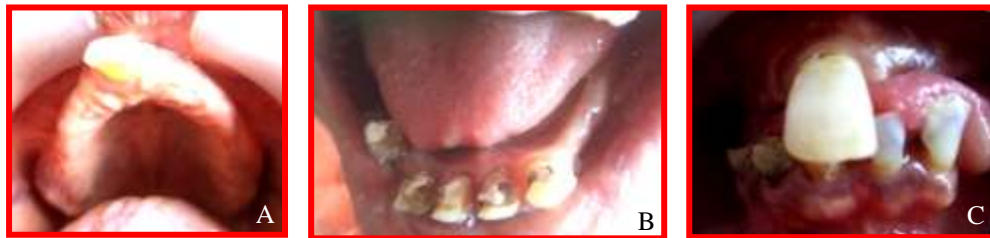

Figure 3. Preoperative status of patient: (A) maxillary arch; (B) mandibular arch; (C) both arches

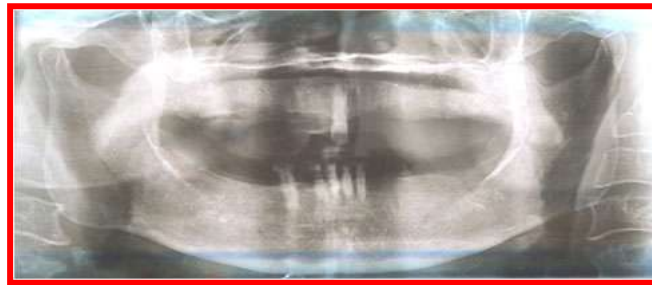

Figure 4. Panoramic radiograph of the patient

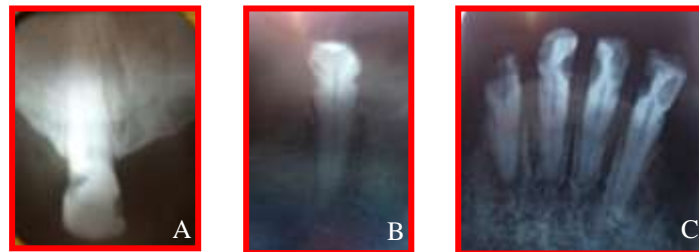


Figure 5. Periapical radiograph of the patient: (A) tooth 11; (B) teeth 42,41,31,32; (C) tooth 44

Patient's maxillary and mandibular preliminary impressions were made with fast setting alginate impression material (Figure 6) and poured in gypsum type III to obtain study cast (Figure 7). Maxillary and mandibular cast were mounted in articulator with vertical dimension and centric relation records. Modifications of abutment teeth were planned on diagnostic cast to evaluate the space for double copings.

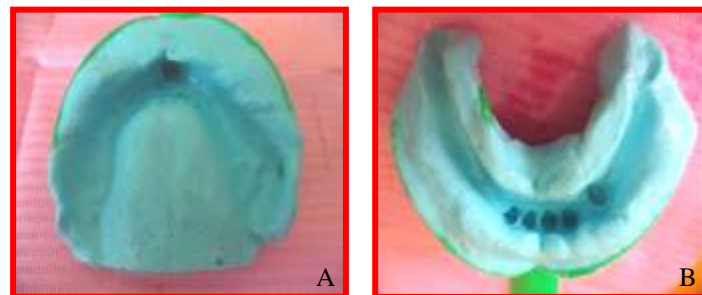


Figure 6. Preliminary impressions: (A) maxillary impression; (B) mandibular impression

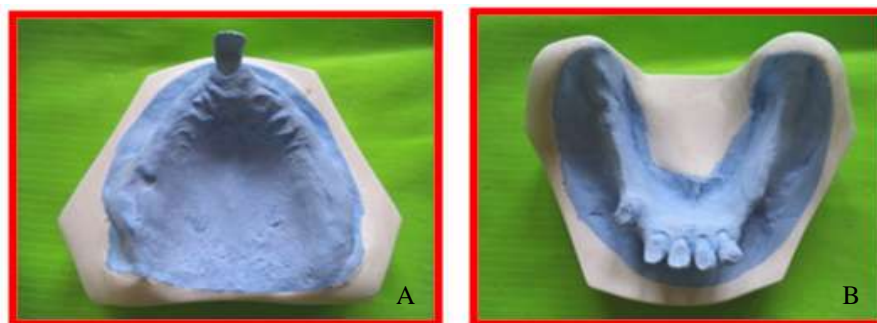


Figure 7. Study cast: (A) Maxillary cast; (B) Mandibular cast

The diagnosis of maxilla is Kennedy class I and mandible is Kennedy class I modification 1.

Prosthodontist should consult a treatment plan with neurologist who treat the patient. Dental treatment planning was explained to the patient and her husband. Her husband signed informed consent. Patient should take a medicine according to neurologist instructions, 60 minutes before starting the treatment. The treatment should be taken in the morning about 45 minutes and accompanied with closed family. The patient was requested to empty his urinary bladder before treatment initiation to avoid urinary urgency and incontinence. A special emphasis was made to treat the patient in compassionate, caring environment to alleviate anxiety and frustration behaviour. The patient's husband was made to sit next to the patient to reduce the anxiety and to help in interpreting the patient's speech.

Treatment for this case was preprosthetic procedure for remaining teeth, fabrication conventional immediate complete denture which denture base was fabricated from heat cured polymerizing acrylics with 1% glass fiber reinforced chopped strand 3 mm for maxillary arch (Figure 8), overdenture of tooth 44 and telescopic denture of abutment teeth 42,41,31,and 32 for mandibular arch (Figure 9). The tooth 11 was extracted utilizing 1 cartridge of 2% lidocaine HCl with epinephrine 1:100000, followed with insertion maxillary immediate complete denture and mandibular denture.

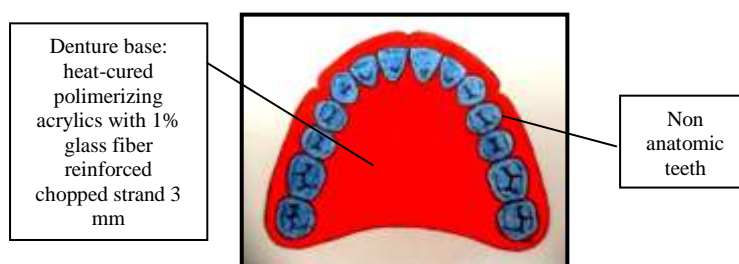


Figure 8. Maxillary complete denture design

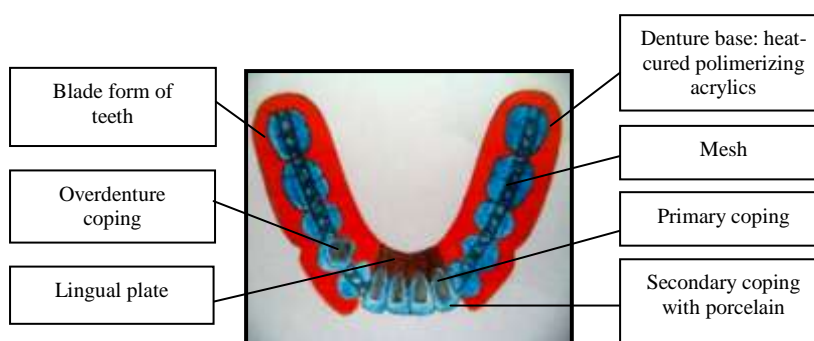


Figure 9. Mandibular denture design

Preprosthetic treatment was oral hygiene instruction, scaling of teeth 11, 32, 31, 41, 42, 44 and endodontic treatment of teeth 32, 31, 41, 42, 44. Glass fiber-reinforced posts with composite core restoration of teeth 32, 31, 41, 42 to maintain retention of the build-up because an extensive damage of the clinical crown.



Figure 10. Teeth 42,41,31,32 post endodontic treatment

Abutment teeth 42,41,31,32 were prepared with tapered wall (approximately 5 degree) and axial wall heights of 4 mm to receive the primary copings with shoulder finish line and kept equigingival. It was ensured that all preparation were parallel to each other with minimal conus to get maximal retention. Retention mechanism of telescopic crown is conical crown with friction retention between primary and secondary coping “wedging effect”.

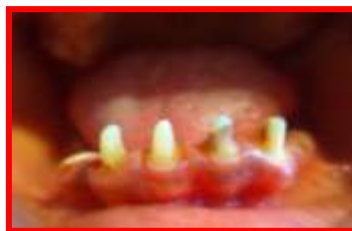

Figure 11. Preparation of teeth 32,31,41,42

Preparation tooth 44 to fabricate dome shaped coping. Short abutment preparation 2 mm on the gingiva margin. Preparation for root canal was 1/3 length as abutment. Preparation antirotation slot on root canal orifice. Length of dowel was 5 mm. Preparation with chamfer finish line. Removed gutta percha was using peeso reamer no 3.



Figure 12. Preparation of tooth 44

Retraction was done by gingival hemostatic retraction paste and a final impression was made with vinyl-polysiloxane material (I-SiL Premium Regular Set Putty and I-SiL Light Body, Spident, USA) a modified one step putty-wash impression technique, especially for tooth 44, light body on tooth pick inserted in root canal. This impression is poured in gypsum type IV (Heraeus Kulzer Moldastone, Germany) to obtain first master model for fabrication overdenture of 44 and primary copings of 42,41,31,32. Marked the finish line with pencil, using pindex system technique in the construction of removable die and the die is trimmed. Wax patterns were prepared on the individual abutment and placed on a surveyor to check the surfaces of 42,41,31,32 parallel to each other. The finish lines on the wax patterns of 42,41,31,32 were kept as shoulder to receive secondary copings. The parallelism and finish lines were critical for frictional resistance and retention of secondary copings.



Figure 13. (A) Wax patterns for primary coping of 42,41,31,32 were checked the parallel to each other, (B)-(C) Wax pattern for coping of 44

The wax patterns were sprued, invested and casted with NiCr alloy. After retrieving, copings were finished and placed on milling machine to get the final parallelism. They were polished and kept ready for cementation.

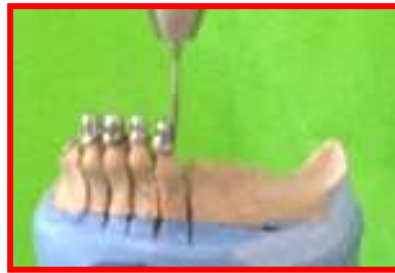

Figure 14. Primary coping was been milling on teeth 42,41,42,31 to maintain coping paralel

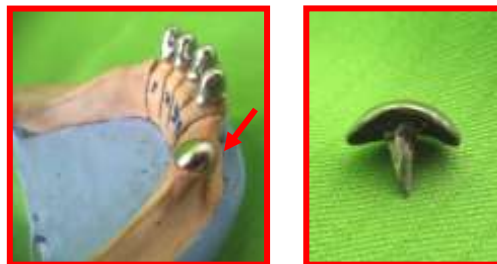

Figure 15. Overdenture coping for tooth 44

The copings were checked for their fit and marginal integrity. They were cemented with glass ionomer cement (FUJI I, GC, Japan).

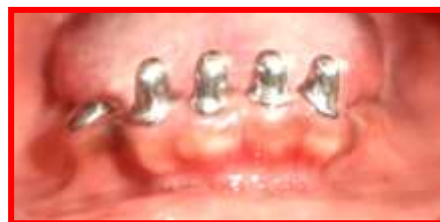

Figure 16. Cemented overdenture coping of tooth 44 and primary coping of teeth 42,41,32,31

Border molding the custom tray of maxillary and mandibular arch utilizing border molding impression material (Peri Compound, GC, Japan). Final impression for maxillary arch was using vinyl polysiloxane material (I-SiL Regular Body, Spident, USA) with mucofunctional technique and poured in gypsum type III to obtain master model. Second final impression for mandibular arch was using vinyl polysiloxane impression material (I-SiL Regular Body and I-SiL Light Body, Spident, USA) with modified one step technique on teeth region, using vinyl polysiloxane impression material (I-SiL Regular Body, Spident, USA) with mucofunctional technique on alveolar ridge and poured in gypsum type IV to obtain second master model.

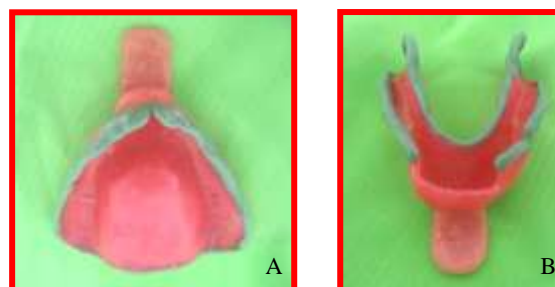


Figure 17. Custom tray after border molding for: (A) maxillary arch, (B) mandibular arch

Fabrication refractory cast, wax patterns for secondary copings were fabricated on refractory cast, the margins of secondary copings were carved to fit the shoulder of the primary copings and designed lingual plate, wax up framework, sprued, invested and casted. These copings with framework were retrieved and finished. The secondary copings and framework were checked intraorally for fit and margins. A wax rim was prepared for maxillary arch and on the framework for mandibular arch, maxillary and mandibular cast were mounted on articulator with vertical dimension and centric relation records.

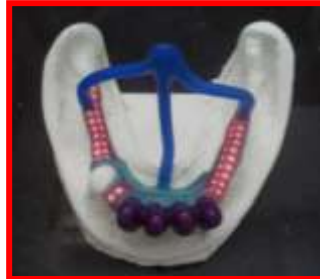

Figure 18. Wax patterns for secondary copings and wax up for framework on refractory cast

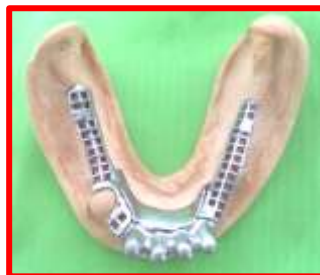

Figure 19. Metal framework and secondary copings

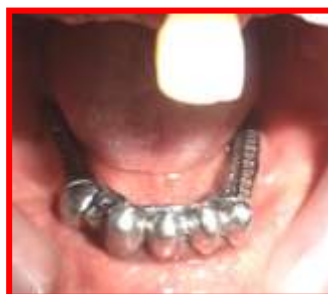

Figure 20. Metal framework and secondary copings were checked intraorally for fit and margins

Teeth shade 4L1.5 were determined with Vita 3D-Master Shade Guide. Built up porcelain for teeth 42,41,31,32.

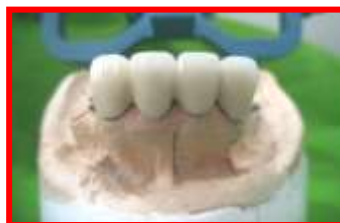

Figure 21. Porcelain built up on secondary coping

Teeth arrangement linear occlusion concept, try in, trimmed tooth 11 and wax-up. Powder of heat cured polymerizing acrylic is 4,36 gr so 1% for glass fiber reinforced chopped strand 3 mm is 0,436 gr. Glass fiber was immersed in silane coupling agent (Gamma-methacryloxypropyltrimethoxysilane/MPS), dry it for 40 minutes and after that put in the oven 115 degree Celcius for 1 hour. Glass fiber is ready to use. Processing maxillary denture with heat cured polymerizing acrylic and 1% glass fiber reinforced chopped strand 3 mm, mandibular denture with heat cured polymerizing acrylic, finishing and polishing. Try in maxillary and mandibular denture.



Figure 22. Glass fiber reinforced chopped strand 3 mm



Figure 23. Glass fiber reinforced chopped strand 3 mm immersed in silane coupling agent (Gamma-methacryloxypropyltrimethoxysilane/MPS)

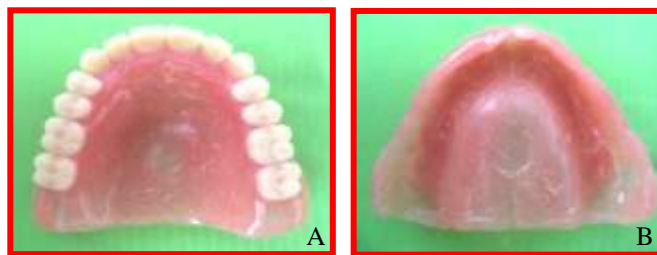


Figure 24. Maxillary denture: (A) polished surface; (B) intaglio surface

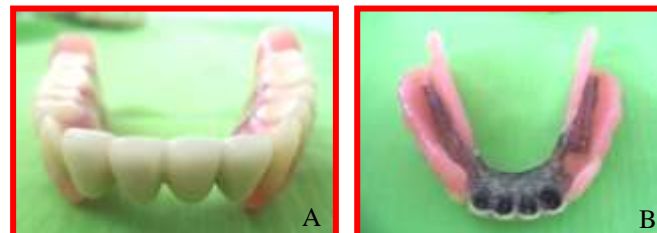


Figure 25. Mandibular denture: (A) polished surface; (B) intaglio surface

The tooth 11 was extracted utilizing 1 cartridge of 2% lidocaine HCl with epinephrine 1:100000, followed with insertion maxillary immediate complete denture and mandibular denture. The patient and her husband were told about follow up 24 hours. When follow up, check retention, occlusion, stability and aesthetics. Instruction, maintenance of denture and oral hygiene should be told to the patient and her husband. Copy written maintenance of denture and oral hygiene can be given, used denture cleanser to clean the denture, and electric interdental brush for clean interdental coping. Follow up program was scheduled after one week, one month, three month intervals for evaluation the prosthesis.

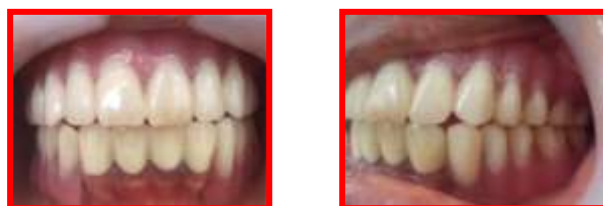

Figure 25. Denture insertion of maxillary immediate complete denture and mandibular denture

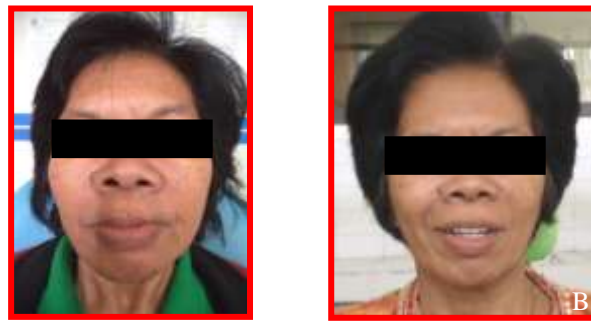

Figure 26. (A) Pretreatment view; (B) Post insertion view of the patient

Follow up after 1 month, maxillary and mandibular denture have good retention, stabilization, support and masticatory efficient.

III. Discussion

Before prosthodontic treatment, dentist should consult with neurologist who treat the patient to modified the treatment. Informed consent was signed by patient or caregiver. Patient with Parkinson's disease should schedule with short appointment less than 45 minutes in the morning because there is less symptoms occurred and 60 minutes after their medication taken, as medications tend to be most effective in that period. The patient was requested to empty his urinary bladder before treatment initiation to avoid urinary urgency and incontinence. Dental chair moved slowly and inclined to around 45 degree to prevent orthostatic hypotension and facilitate patient swallowing. Aspirating tip can be used to suction the saliva. The stress is know to exacerbate the tremor and uncontrolled movement during treatment. To prevent anxiety or frustration, dentist introduced herself each time, used simple words, short sentences, limit the use of facemask, smiling and direct eye contact. The patient's husband was made to sit next to the patient to reduce the anxiety and to help in interpreting the patient's speech.⁵⁻⁸

Maxillary immediate complete denture was chosen because patient refuse extraction of tooth 11 before fabricating denture, patient can not slice food so it will make food intake disturbance, and extraction of tooth 11 after fabricating denture to help maintain muscle support and maxillomandibular relationship, assist muscle coordination for patient with Parkinson's disease and facilitate shape and size of tooth 11. Extraction of tooth 11 because there is only one tooth with caries on cervical, periodontal disease (mobility teeth, alveolar resorption) elongation 1,5 mm, labioversion and mesial migration so it cannot be abutment teeth, and make difficulty tooth arrangement. Patient with Parkinson's disease need comfortable so with fabricating immediate denture can reduce pain post extraction (because extraction region is conserve) and prevent more resorption.

Mandibular telescopic denture with abutment of teeth 42,41,31,32 because of lost of many teeth, remaining teeth only four teeth, weakness abutment for conventional removable partial denture but extraction to fabricate complete denture is not recommended because of extraction lost of support and proprioceptive from teeth and periodontal ligament. Fabrication telescopic denture is more esthetic because there is no clasps on abutment teeth and telescopic denture combine good retentive and stabilization with splinting effect. Telescopic denture can reduce lateral force on abutment teeth with force distribution. Conical crowns or tapered telescopic crowns that exhibit friction only when completely seated using a "wedging effect." The magnitude of the wedging effect is mainly determined by the convergence angle of the inner crown; the smaller the convergence angle, the greater is retentive force. Copings of minimal taper (approximately 5 degrees) require a height of about 4 mm to achieve a significant retention.^{9,10}

Overdenture of tooth 44 is chosen because height of occlusogingival 3 mm (height for making telescopic denture abutment is 4 mm minimal), prognosis is compromised for individual tooth with periodontal disease (alveolar resorption, lost of attachment, mobility, and oblique), from radiographic examination, crown to root ratio is available to retain. The finishing line is equal gingival. Overdenture coping should self cleansing.¹¹

Taking impression with fast setting impression because patient with Parkinson's disease difficult to keep the mouth open. Recording maxillomandibular relationship with repeat exercise. Patient and exercise can be helped to improve maxillomandibular relationship. Jaw exercise may be helped. Difficulty to control and maintain denture because of tremor, rigidity of orofacial muscles and drooling saliva so retention, stabilization, and support should be achieved.^{5,6}

Arrangement teeth with linear occlusion concept to prevent combination syndrome. Non anatomic on maxilla and blade form of teeth on mandible were selected in an attempt to stabilize occlusion in the maximal intercuspal position and improved mastication. The denture should be fabricated by using metal denture base or

high impact denture base resin. Denture base with 1% glass fiber reinforced chopped strand 3 mm will increase impact strength and transverse strength so the denture base will not easily broken.^{5,6,12,13}

Extraction tooth utilized with anestheticum contain epinefrin should be carefully because patient treated with levodopa that can be promoted blood pressure and pulse rate. Epinephrine less than 0,05 mg is safe and utilized 3 cartridges of 2% lidocaine HCl with epinephrine 1:100000 in 30 minutes. Monitoring the vital sign.^{5,6}

Maintenance oral hygiene of patient with Parkinson's disease is compromised because of manual dexterity. Patient and care giver should be given oral hygiene instruction and follow up important to prevent potential complication for next time. Copy written about maintenance can be given to the patient and caregiver to prevent forget instruction. Patient and caregiver told about using electric interdental tooth brush to clean abutment teeth of telescopic denture and to prevent retained food.^{14,15}

Fabrication and insertion of maxillary immediate complete denture, overdenture, and telescopic denture patient with Parkinson's disease was successful with efficient cost and time. One month follow up, there is no complication and good retention, stability, esthetic and improved difficulty in chewing.

IV. Conclusion

Knowledge and empathy were essential in management of maxillary immediate complete denture, mandibular overdenture and telescopic denture thus improved difficulty in chewing, esthetic, and quality of life of Parkinson's disease patient.

References

- [1]. Parkinson's Disease Society. Professional's guide to Parkinson's disease. London: Parkinson's Disease Society of the United Kingdom. 2007: 1-3.
- [2]. Scully C. Medical problems in dentistry. 6th ed. China: Elsevier. 2010: 329-31.
- [3]. Hoehn MM, Yahr MD. Parkinsonism: onset, progression, and mortality. *Neurology* 1998; 50: 318–334.
- [4]. Bakke M, Larsen SL, Lautrup C, Karlsborg M. Orofacial function and oral health in patients with Parkinson's disease. *Eur J Oral Sci* 2011;119:27-32.
- [5]. Rajeswari CL. Prosthodontic consideration in Parkinson disease. *People's Journal of Scientific Research*. 2010; 3(2): 45-7.
- [6]. Neha S, et al. Prosthodontics considerations in the management of Parkinson's disease- a review. *UJMDS* 2014,2(4):163-7.
- [7]. Haralur SB. Clinical strategies for complete denture rehabilitation in a patient with parkinson disease and reduced neuromusculr control. *Hindawi Publishing Corporation*. 2015:1-5.
- [8]. Zlotnik Y, et al. Disorders of the oral cavity in parkinson's disease and parkinsonian syndromes. *Hindawi Publishing Corporation*. 2015:1-6.
- [9]. Goswami R, et al. Telescopic overdenture: perio-prostho concern for advanced periodontitis. *Contemporary Clinical Dentistry* 2013; 4(3): 402-5.
- [10]. Kwon HB, Roh YH, Lee SH. The comparison of initial retentive force in differentt double crown systems. *J Korean Acad Prosthodont* 2006; 44(6): 677-82.
- [11]. Kalpana C, Vamsi PK. Seeing the unseen: preventive prosthodontics: use of overlay removable dental prosthesis. *Annals and Essences of Dentistry* 2010; 2(3): 44-9.
- [12]. Singh S, Manvi P, Singh H. Prosthodontic management of severely resorbed mandibular ridge in a patient with parkinson disease using neutral zone technique- a clinical report. *Indian J Multidisciplinary Dent* 2014;4(2):944-8.
- [13]. Watri D. The effect of glass fiber addition of denture base material heat polymerized acrylic resin on impact and transverse strength. Medan, University of Sumatera Utara: Skripsi 2010.
- [14]. Bhat V, et al. Complete denture treatment protocol in parkinson's disease: a case report. *JIADS* 2011; 2(2):63-5.
- [15]. Al-Omari, et al. Oral rehabilitation of parkinson's disease patient: a review and case report. *Hindawi Publishing Corporation*. 2014:1-4.